Diagnostics of Hirschsprung's disease from the point of view of its pathophysiology.

M.D. Levin, MD, PhD, DSc. Radiologist,

Department of Pediatric Radiology of the 1-st State Hospital, Minsk, Belarus.

Dorot-Netanya Geriatric Medical Center, Israel.

nivel70@hotmail.com; michael.levin@dorot.health.gov.il

https://www.anorectalmalformations.com

The aim of this research is to study the x-ray symptomatology of Hirschsprung's disease (HD) based on analysis of radiographs and video published on the Internet and on the basis of our own research to increase the accuracy of X-ray diagnosis HD**. Material and methods:** An analysis of 56 radiographs and 2 videos of patients with a histologically confirmed diagnosis of Hirschsprung's disease was performed, including 25 radiographs from our own practice and 31 radiographs and 2 videos from articles published in PubMed and PMC. As examples of cases without HD, radiographs from our own practice are given, where HD was excluded on the basis of manometric detection of rectoanal inhibitory reflex (RAIR). For X-ray analysis, a contrast marker of known diameter was used, which was located near the anus. This made it possible to measure the length of the anal canal, as well as to determine the true parameters of different parts of the intestine, which were compared with previously published age standards. **Results:** In addition to the symptoms described in the literature (the transition zone, microcolon, retention of contrast on post evacuation film, and the rectosigmoid ratio < 1) have been revealed new anatomical symptoms of HD (absence of an anterior displacement of the anal canal axis, expansion of the retrorectal space, and symptom of "frozen" segmentation) and physiological symptoms (the

absence of the RAIR and defecation reflex). The shortening of the anal canal, with a noticeable displacement of it towards the pubis, as well as the presence of PAIR and wide opening of the anal canal during rectal emptying are symptoms, the combination of which makes it possible to exclude HD. **Conclusion.** The use of all radiologic symptoms increases the accuracy of the HD diagnosis. The algorithm of diagnostics is offered.

Keywords: algorithm; anal manometry; Hirschsprung's disease; pathophysiology of congenital agangliosis; X-ray diagnosis.

Introduction Hirschsprung's Disease (HD) is relatively common in children. Surgical treatment is aimed at removing the aganglionic gut and repairing the intestinal tract. Despite some achievements of recent years, the diagnosis of the disease is not always timely. After surgical correction, functional problems arise [1]. The final diagnosis of HD is based on a rectal biopsy, but the diagnostic process always begins with a contrast enema, which in some cases allows a reliable rejection of the diagnosis, and in 70-90% of cases establish the location of the transition zone [2]. Some authors use a manometric study to exclude HD, but the frequency of its use decreases every year [3].

Normally, during early embryonic development, nerve cells invade the primary intestine in a craniocaudal direction. The enteric ganglia are interconnected to form two plex that extend along the length of the bowel: an outer myenteric (Auerbach) plexus running the full length of the gut, and an inner submucosal (Meissner) plexus, found only in the small and large intestine. The myenteric plexus develops first and is situated between the longitudinal and circular smooth muscle layers, and is involved in motility, while the submucosal plexus, which forms later, regulates motility, blood flow, and the transport of ions across the intestinal epithelium [4].

Gut motility is controlled by interdependent mechanisms including neural, such as the enteric ganglia, and nonneural, such as the interstitial cells of Cajal (ICC) [4, 5]. The interstitial cells of Cajal serve as pacemaker cells creating and propagating slow waves that lead to smooth muscle contraction in the gut [4].

The absence of enteric ganglion cells of the myenteric and submucosal plexus along variable portions of the GI tract results in HD, which is characterized by sustained contraction of the aganglionic bowel segment, leading to intestinal obstruction and distension of proximal segments (megacolon). No matter how far from the anus the aganglionic segment begins, it always reaches the middle of the anal canal [5].

In 80–85% of HD cases, the aganglionic region is limited to the rectum and sigmoid colon. Long segment disease occurs in up to 20% of cases and is characterized by aganglionosis extending proximally to the sigmoid colon. Total colonic aganglionosis is more rare, occurring in 3–8% of patients with HD [14]. Another rare variant is ultra-short segment disease, affecting only the distal rectum (≤2 cm) [5].

Clinical symptoms of Hirschsprung's Disease [6].

Infants	Older children
Enterocolitis (diarrhea) Failure to pass meconium in the first 24 hours of life Infrequent, explosive bowel movements; difficult bowel movements Jaundice Poor feeding Progressive abdominal distention Tight anal sphincter with an empty Rectum Bilious vomiting	Absence of soiling or overflow incontinence Chronic progressive constipation, usually with onset in infancy Failure to thrive Fecal impaction Malnutrition Progressive abdominal distention

Anorectal Manometry (ARM)

During ARM, a flexible catheter, with a non-latex balloon at its distal end, is introduced into the rectum. The sensor measures intraanal pressures during the study. The rectoanal inhibitory reflex (RAIR) is the reflex relaxation of the internal anal sphincter (IAS) in response to rectal distention. This reflex is present in individuals with normal intrinsic innervation of the intestine and is absent in those with HD (**Figure 1**). In a study by Jarvi et al the specificity and positive predictive value of ARM for HD were 83% and 80%, respectively. They concluded that if RAIR is present, a rectal biopsy may not be required [7].

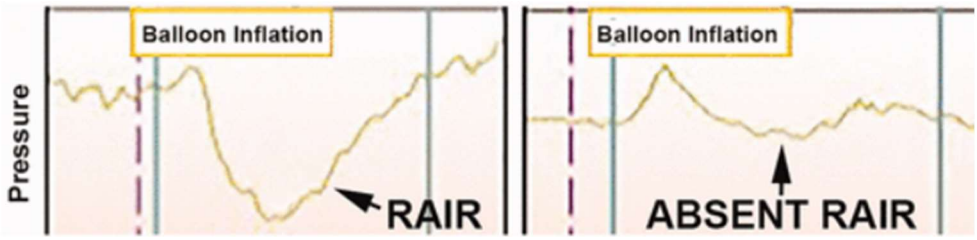

Figure 1. Anorectal manometry. Representative single sensor pressure tracings from a different individual with a normal RAIR (left) and a patient with an absent RAIR (right). From an article by Ambartsumyan et al [5].

Contrast Enema

X-ray anatomical findings that are suggestive of HD include the presence of a radiographical transition zone with proximal dilated bowel, microcolon, retention of contrast on post evacuation film, irregular colonic contractions, mucosal irregularity, and an abnormal rectosigmoid ratio. The radiographic location of the transition zone has been shown to correlate with the length of the aganglionic segment, specifically of the rectosigmoid segment, and may aid in surgical procedure planning. However, correlation was lower in segments proximal to the rectosigmoid and in children younger than 3 months of age. This further highlights the importance of intraoperative biopsies to direct surgical planning [5]. In a systematic review of the literature, de Lorijn et al reported that contrast enema had lower mean sensitivity and specificity of 70% and 83%, respectively, when compared to ARM and rectal suction biopsy. Furthermore, contrast enema in the neonatal period has been shown to be less reliable than in older children [8].

Rentgen Functional findings. Nusslé et al showed for the first time the X-ray manifestation of the rectoanal inhibitory reflex during a contrast enema in the form of penetration of the contrast medium into the upper part of the anal canal [9]. Measurement of anal pressure during a barium enema revealed that the penetration of barium into the upper part of the anal canal in front of the tip of the enema is accompanied by a decrease in anal pressure, and after the disappearance of barium from the anal canal, anal pressure is restored to the basal level. The use of a contrast marker near the anus improves visualization of the X-ray equivalent of the RAIR [10].

Ornö et al применили sonographic method for examination of the rectoanal inhibitory reflex. The RAIR was elicited by injecting 20 мл water into the rectum, and the events in the bowel were recorded on video for offline analysis. Among 28 children (median age, 21 months; range, 5 days–12 years; 11younger than 1 year and 7 between 1 and 2 years) with suspected HD, in 3 with aganglionosis, RAIR was absent. In 17 children, the RAIR was present and all of these children had normal histologic findings. In 8 children, sonography did not show the reflex despite normal histologic findings [11] (29% false-negative results).

von Steyern et al used an enema with Omnipaque 140 mg/ml for the differential diagnosis of chronic constipation. After the contrast medium had filled the rectum and the distal part of the sigmoid, two sequential fast (<5 s) injections of 20 ml cold contrast agent (16 °C) were performed during documentation of the low pulse fluoroscopy sequences for about 30 s each. The contrast medium was injected until a transition zone was identified or the whole colon was filled. Five boys and one girl (median age, 7.5 days) were diagnosed with HD. The negative predictive value of the rectoanal inhibitory reflex was 100%. A contrast enema with signs of HD in combination with an absent RAIR had the specificity of 98% and sensitivity of 100% for HD [12].

Rectal Suction Biopsy (RSB)

The gold standard for an HD diagnosis is a rectal biopsy. The density of ganglion cells declines toward the inferior end of the anal canal. Since the distal part of the anal canal develops from the ectoderm, it does not carry the pathological changes that are characteristic of HD. This zone is normally represented by hypoganglionosis or possibly aganglionosis and the recommendation that biopsies to exclude HD should be taken proximal to this zone,> 2 cm above the mucocutaneous junction / anal verge [5].

Analysis of the literature shows that in HD, apart from the absence of RAIR, there is no information about the function of the external anal sphincter (EAS), puborectal muscle (PRM), and levator plates (LP). This information can be useful for improving the accuracy of the preoperative diagnosis, as well as for choosing the optimal method of surgical treatment.

The aim of this research is to study the x-ray symptomatology of Hirschsprung's disease based on analysis of radiographs and video published on the Internet and on the basis of our own research to increase the accuracy of X-ray diagnosis HD.

Material and methods An analysis of 56 radiographs and 2 videos of patients with a histologically confirmed diagnosis of Hirschsprung's disease was performed, including 25 radiographs from our own practice and 31 radiographs and 2 videos from articles published in PubMed and PMC. In 18 articles, only frontal radiographs were given. Lateral radiographs have been reported in 13 articles, mostly in the past 20 years. As examples of cases without HD, radiographs from our own practice are given, where HD was excluded on the basis of rectoanal inhibitory reflex (RAIR) manometric detection.

For X-ray analysis, a contrast marker of known diameter was used, which was located near the anus. This made it possible to measure the length of the anal canal, as well as to determine the true parameters of different parts of the intestine, which were compared with previously published age standards [10].

Results.

1. Frontal and lateral images. In many cases, a frontal radiograph is sufficient to diagnose HD and determine the level of the transition zone **(Figure 2a)**. However, in some patients, a frontal radiograph may be unreliable. The short aganglionic segment may be closed by an extended rectum. To visualize it, a lateral radiograph is required (Figure 2b). In infants, the difference in width between healthy and aganglionic segments may be negligible. A lateral radiograph and x-ray study of the RAIR may be diagnostic **(Figure 3).**

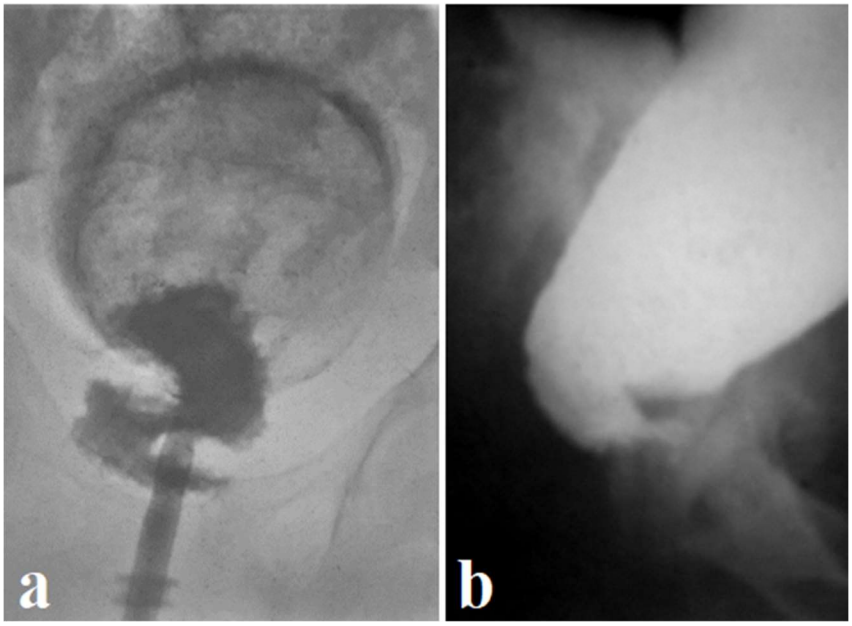

Figure 2. Frontal (a) and lateral (b) radiographs patients with HD.

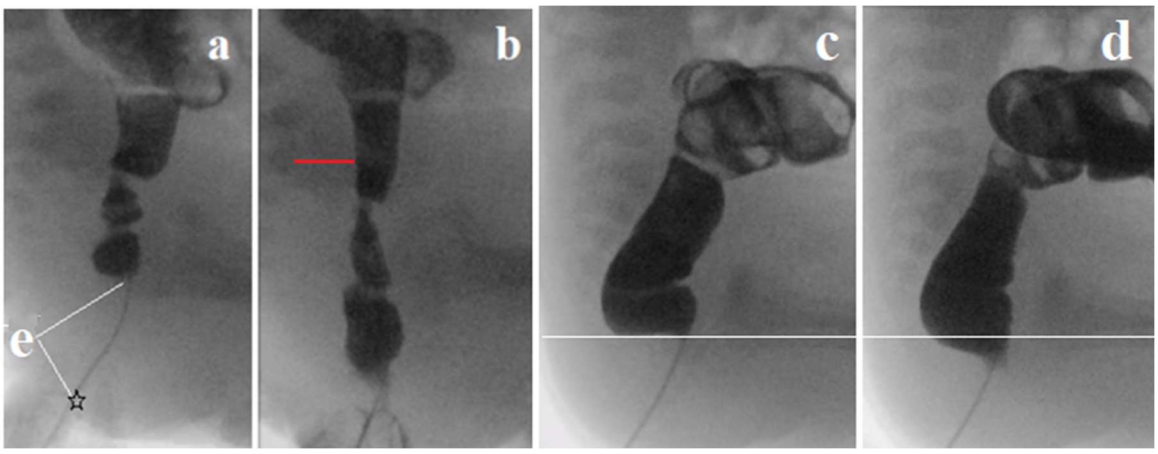

Figure 3. Video excerpts from von Steyern's article [12] with permission from the authors. A 1-month-old boy later diagnosed with Hirschsprung disease. The rectoanal inhibitory reflex is absent. At the beginning of the study (**a**), the contrast agent in the rectum was divided into 3 segments by circular contractions ("e" - anal canal). The end of the catheter is located between the upper and middle segments. As a result of the introduction of a contrast agent, the volume in the lower segments increased, which indicates an increase in pressure. Then (**b**) segments (symptom of frozen segmentation) partially moved into the anal canal. There is a sharp expansion of the retrorectal space (red line). (**c-d**) A 1-month-old boy without Hirschsprung disease. The rectum is wide with smooth walls. The axis of the anal canal is displaced anteriorly from the rectum. During the injection of the contrast agent, it penetrated into the upper part of the anal canal (RAIR).

Analysis. The anus is located where the contrast agent has stained the buttocks around the catheter (asterisk). The true length of the anal canal (e), located between the pubococcygeal line and the anus, is 1.7 cm at this age [13]. Based on this, the width of the distal rectal segment is 0.6 cm (the minimum normal limit for this age is 1.3 cm). Retrorectal space, i.e. the distance from the posterior wall of the rectum to the vertebra (red line) is 0.8 cm with the age norm not exceeding 0.1 cm. Therefore, we are talking about a sharp narrowing of the rectum and a sharp expansion of the retrorectal space. Throughout the study, the axes of the rectum and the upper part of the anal canal completely coincide. This means that the PRM did not contract and not pull the upper part of the anal canal anteriorly. During the emptying of the contrast medium, the rectum did not participate in this process, and there was no expansion of the anal canal, i.e. there was no contraction in levator plates. Consequently, emptying occurred without a defecation reflex. Three segments of the rectum expanded and moved caudally, but retained the same shape - symptom of frozen segmentation. Thus, the lack of relaxation of the IAS was not the only symptom of HD. A sharp narrowing of the rectum and expansion of the retrorectal space are symptoms of colitis. It can be added that contrasting the anus could facilitate the analysis of the study.

Analysis of the literature indicates that in order to improve the diagnosis of HD, it is necessary to perform at least frontal and lateral radiographs. Video analysis and frontal radiograph at 24 hours can confirm the diagnosis if in doubt.

2. Abnormal rectosigmoid ratio <1.

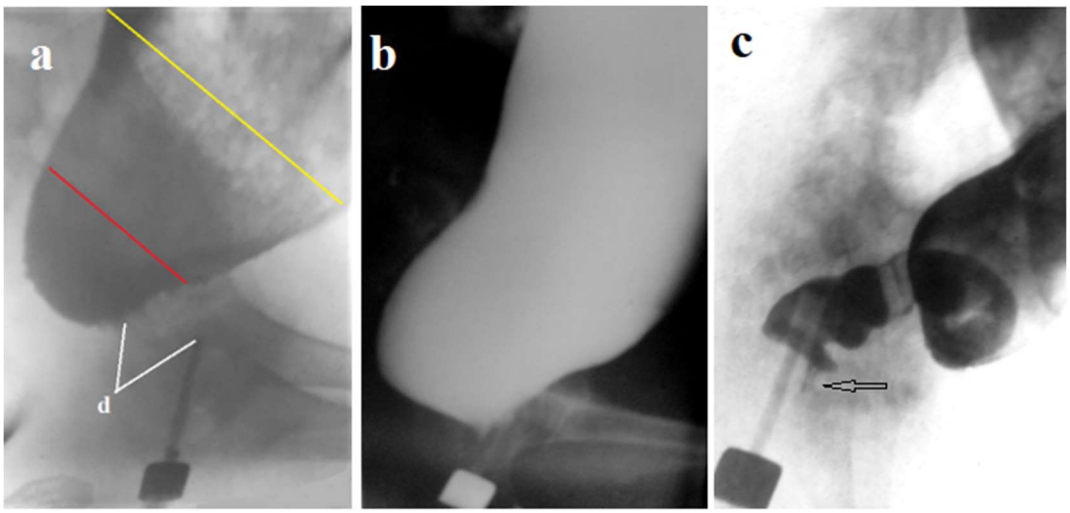

Figure 4. (a-b) Rectosigmoid ratio in HD and in functional constipation (FC). **(a)** A 10-year-old girl with a short (d = 2.5 cm) aganglionic segment, which is in a contracted state. The width of the rectum (red line) is 6.4 cm. A maximum age norm is 4.1 cm. The width of the sigmoid colon is 11 cm. A maximum norm is 2.6 cm). **(b)** An 8-year-old male with FC. He has a rectosigmoid ratio <1. However, the rectal width is 5.1 cm. It greater than the maximum normal limit (4.1 cm), and the anal canal length of 1.4 cm is significantly less than the minimum normal limit (2.6 cm). **(c)** An 11-months-old male with HD with a typical x-ray picture of HD. Rectosigmoid ratio <1. The arrow shows the contrast agent that has penetrated the top of the anal canal in front of the enema tip, which can be mistaken for RAIR.

Analisis.

On the radiograph 4.a, the rectum proximal to the contracted segment is narrower than the sigmoid colon, and the question may arise, is it aganglionic? Measurement shows that it is much wider than the maximum normal limit. Rectosigmoid ratio <1 is due to the fact that the limits of the expansion of the rectum are limited by the size of the small pelvis, while the expansion of the sigmoid colon is not limited. On the radiograph 4b, the rectosigmoid ratio is <1

for the same reason. But a sharp shortening of the anal canal is indicative of a stretching of the pelvic floor muscles, which is called perineal descending syndrome. On the radiograph 4.c. traces of contrast agent in the upper part of the anal canal have no volume. The contrast agent lingered in the folds of the mucosa as evidence of an inflammatory process.

In all 12 patients with HD, where it was possible to measure the length of the anal canal, including 5 patients with a short form of aganglionosis, the length of the anal canal was within the age norm.

3. Irregular colonic contractions and mucosal irregularity

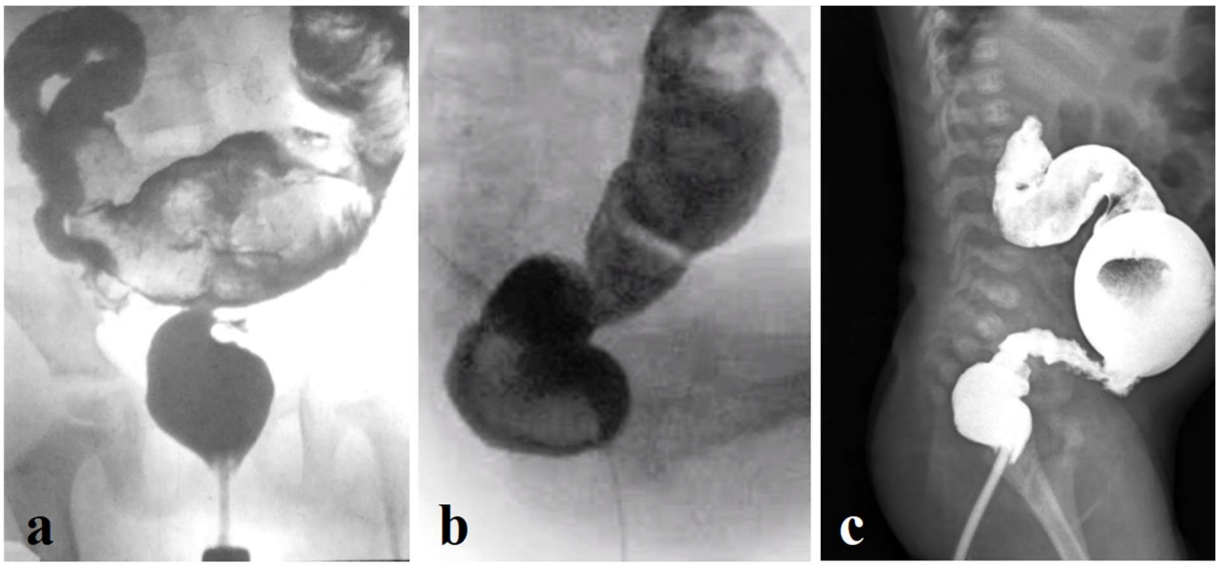

Figure 5. Irregular colonic contractions (segmentations) and mucosal irregularity. **(a)** A 4-year-old boy with Hirschsprung disease. A large fecal stone is stuck in the sigmoid colon. **(b)** A 3-year-old boy later diagnosed with Hirschsprung disease. The rectoanal inhibitory reflex is absent. The rectum is represented by segments of different sizes [12]. **(c)** A 6-months-old girl with Hirschsprung disease. A wide fecal stone stuck over a narrow segment of the sigmoid colon with mucosal irregularity that is typical of colitis.

Discussion. It is obvious that each of these patients went to the hospital due to a sharp deterioration in their condition: prolonged absence of stool, fever, vomiting, and/or diarrhea. They could not live 3-4 years with wide fecal stones fixed between the spasmodic segments of the colon. Colonic narrowing and segmentation, as well as mucosal irregularity, are symptoms of enterocolitis.

Enterocolitis is caused by intestinal obstruction and makes it worse. It is noteworthy that not all segments of the intestine are narrowed, i.e. being involved in the inflammatory process. In figures (a) and (c), the rectum has a normal shape and contours. In patients without enterocolitis, the width of the aganglionic segment may be less than the age norm **(Figure 6.a)** or within the normal range **(Figure 6.b)** but never exceed the normal range.

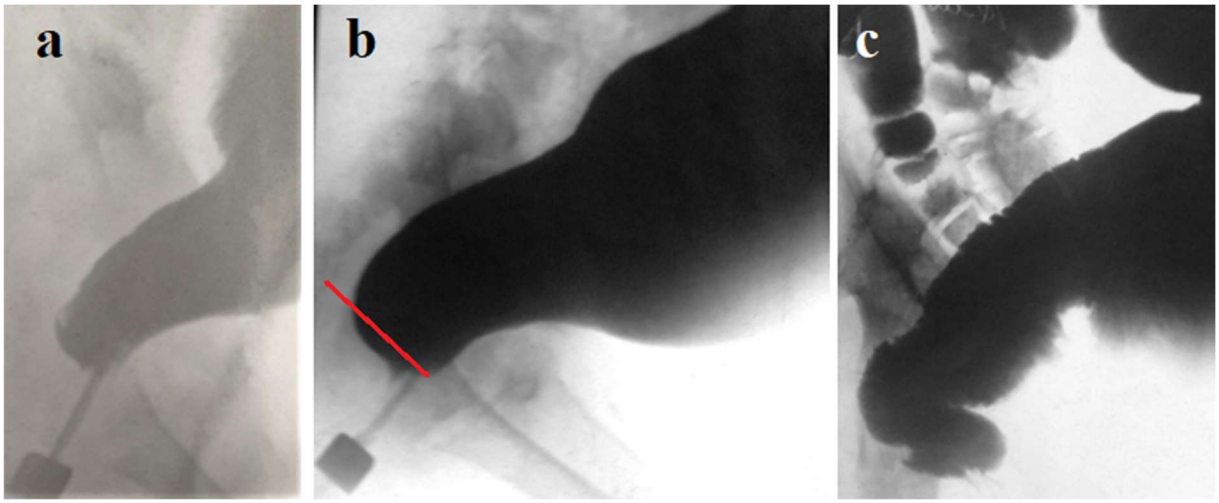

Figure 6. Radiographs of anorectum in patients with HD without segmental contractions. In each case, the rectosigmoid ratio is <1. On radiographs (a, b) in children over 5 years of age, the width of the rectum (a) is 2 cm, (b) - 3 cm, with a minimum age width of 3 cm. The length of the anal canal is within the age norm, and the axis of the anal canal coincides with the rectal axis. (c) The contours of the rectum are finely toothed, indicating an inflammatory process.

Analysis. Thus, the aganglionic segment of the intestine is in a spasmodic state during the inflammatory process - colitis. Without enterocolitis, its width can be within normal limits. The sigmoid colon is expanded due to a violation of the passage throughout the rectum since there is no conductive peristalsis in it. Unlike functional constipation, the rectum is usually not dilated and the length of the anal canal is not shortened. There is no IAS relaxation on fluoroscopy as evidence of RAIR. An additional symptom of HD is the lack of signs of PRM contraction. Normally, the axis of the anal canal coincides with the rectal axis only in infants (**Figure 7.a**). In older children, as a result of the periodic contraction of the PRM, which, during the retention of feces, pulls the upper part of the anal canal toward

the pubis, a horizontal branch of the rectum is formed and the axis of the anal canal is displaced anteriorly (**Figure 7.b**).

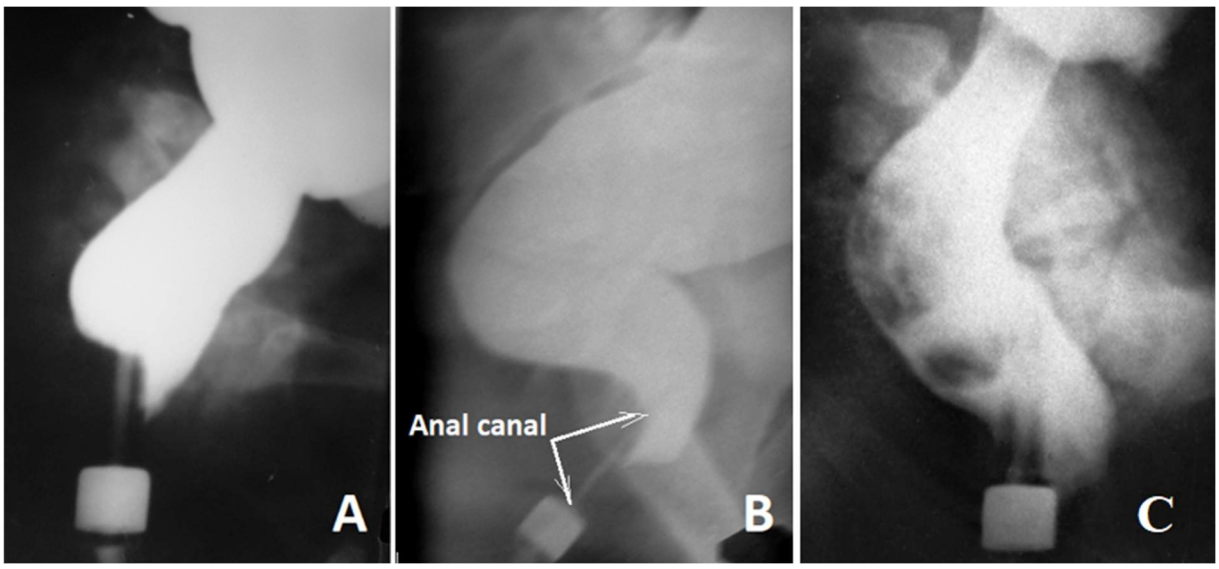

Figure 7. Lateral radiographs of the anorectal zone of patients without pathology of the digestive system. **A).** The penetration of barium into the upper part of the anal canal in front of the tip of the enema determines in infant as a result of IAS relaxation. The posterior wall of the anal canal is pressed against the tip by the contracted PRM. The axis of the anal canal almost coincides with the axis of the rectum. The anorectal angle is obtuse. **B)**. In a patient of 14 years of age, the displacement of the rectum and the upper part of the anal canal is determined as a result of periodic contraction of the PRM for many years. The curved rectum forms a vertical and horizontal branch. The anorectal angle became acute. Relaxation of IAS is determined. **C)**. During the barium enema, an attempt was made to defecate, which did not take place due to the contraction of the subcutaneous part of the external anal sphincter. The wide opening of the anal canal is determined as a result of the contraction of the levator plates as one of the components of the defecation reflex [14].

The absence of a horizontal branch of the rectum and the coincidence of the axes of the rectum and anal canal was found in 4 patients. It was always combined with the rectosigmoid ratio <1. At the same time, the rectum was not narrow but never exceeded the normal limits. We consider this symptom typical for HD because in our practice we have never observed it with other diseases. This symptom

suggests that the rectum is not connected by nerve pathways with the PRM and therefore the expansion of the rectum does not cause a reflex contraction of the PRM, as it normally happens about 7 times per hour. However, in 4 patients with HD, radiographs show an anterior displacement of the anal canal axis (**see Figure 4.a)** and/or the presence of a horizontal rectal branch (**Figure 8**).

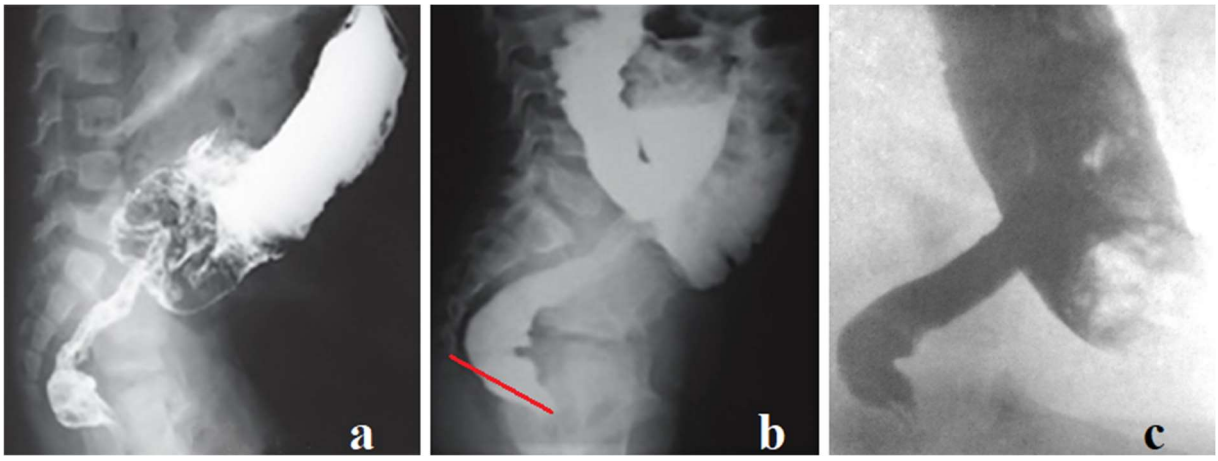

Figure 8. Lateral radiographs of patients with HD. In each case, a small horizontal branch of the rectum and a significant narrowing of the rectum are determined. (a-b) From article Oulad Said [15].

Analysis. In a 3-year-old child (a) the horizontal branch of the rectum is noticeably shorter than in a 6-year-old patient (b). This is due to the fact that the vertical branch of the rectum remains next to the coccyx, while with age, the size of the perineum increases, and the distance between the coccyx and the anus increases. If the rectum had a normal width, then the axis of the anal canal would pass through the rectum. The measurement of the horizontal distance between the last coccygeal vertebra and the anorectal junction was found to be the same in patients of the same age (Figure 6.a versus Figure 8.a) and (Figure 6.b versus Figure 8.b - red line). The presence of an anorectal angle of more than 90 in each case confirms the assumption that there is no contraction in the PRM. An obtuse anorectal angle would be more evident if a tip with a contrast marker was used near the anus.

Thus, the X-ray analysis showed that the expansion of the rectum in patients with HD does not cause a contraction of the PRM.

Discussion As shown in a systematic review de Lorijn et al, the sensitivity and specificity of contrast enema (12 studies for a total of 425 patients) were significantly lower than those of anorectal manometry and rectal suction biopsy, with mean sensitivity and mean specificity of 70% and 83%, respectively [16]. According to Wong et al, the sensitivity of the 24-h delayed film was 85.7 % and the specificity was 17.6 % [17]. However, the diagnosis of HD is actually was based on 4 X-ray anatomical symptoms: transition zone with proximal dilated bowel, microcolon, retention of contrast on post evacuation film, and an abnormal rectosigmoid ratio (<1). As shown above, none of these symptoms are 100% reliable. An increase in the diagnostic accuracy of a contrast enema can be achieved in three ways: (1) optimization of the examination program; (2) comparison of radiographic images of anorectum with normal specimens of anorectal anatomy; (3) studies of anorectal reflexes.

1. Optimization of the examination program.

a) Contrast agent. For chronic constipation with signs of acute deterioration, a water-soluble contrast agent is preferred. In other cases - a barium enema.

b) Using a contrasting mark of a known diameter on the tip of the enema, which should touch the anus allows to measure the length of the anal canal, determine the location of its axis, and use radiometric analysis to compare the obtained data with age standards.

c) Filling the colon with a contrast agent up to the splenic flexure or including the transition zone (frontal radiograph).

d) Transfer of the patient to the lateral position (lateral radiograph). Video recording (or radiographs) to fixate the relaxation of the IAS (RAIR) and the defecation.

e) Radiograph after emptying and/or after 24 hours.

2. **Comparison of radiographic images with normal specimens of anorectal anatomy (Table 1).**

Table 1. Significance of X-ray symptoms in diagnosis of Hirschsprung's disease

X-ray symptoms	Hirschsprung's disease		Without Hirschsprung's disease
	100%	Doubtful symptom	100%
Obvious transition zone with distal microcolon	x		
Rectosigmoid index <1 with non-dilated rectum	x		
Rectosigmoid index <1 with dilated rectum		x	
Rectosigmoid index <1 with dilated rectum and anal canal shortening			x
Rectosigmoid index <1 without horizontal branch of the rectum	x		
Symptom of "frozen" segmentation	x		
Expansion of the retrorectal space		x	
Shortening of the anal canal			x
Relaxation of IAS (RAIR)			x
Defecation reflex (wide opening of the anal canal)			x

The symptom of "frozen" segmentation, ie, segmentation of the intestine that does not change over time, indicates the absence of peristalsis and therefore is a convincing sign of HD. As can be seen from the table, a combination of several symptoms will increase the accuracy of HD diagnosis. At the same time, the detection of normal anorectatum reflexes (RAIR and/or defecation reflex) allows excluding HD and avoiding aspiration biopsy.

Unfortunately, the pathophysiology of HD is poorly understood. It is well known that in HD there are no ganglia of Auerbach and Meissner plexuses. The aganglionic gut, no matter how high it starts, stretches to the rectum and includes the upper part of the anal canal. Because of this, in HD patients during an increase in pressure in the rectum, instead of a decrease in pressure in the upper part of the

anal canal as a result of IAS relaxation, there is an increase in anal pressure (**see Figure 1)**. This means that there is some kind of connection between the rectum and the anal canal. But we have no information about which of the sphincters of the anal canal responded with a contraction (IAS, EAS, or PRM?). Interstitial cells of Cajal (ICCs) are pacemaker cells involved in facilitating neurotransmission and the generation of slow electrical waves necessary for colonic peristalsis. Their distribution has been found to be abnormal in the aganglionic and ganglionic colon in Hirschsprung's disease [18]. However, the role of these changes in HD has not been established.

It is known that normally there are sensory elements in the rectum that react to rectal pressure and transmit information to the S2-S4 of the spinal cord, where the nerve centers responsible for the retention of feces and defecation are concentrated [19-20]. We did not find studies on the reaction of IAS, EAS, PRM, and levator plates to rectal stretching, anal canal stretching, etc in patients with HD. Porter showed that pressure sensing elements are located in the 6 cm of the rectum, and are absent in the sigmoid colon [19]. This gives hope that in the short forms of HD, elements of the normal physiology of the anorectum may be preserved (contraction of EAS in response to urge pressure and contraction of levator plates to defecation pressure). Research in this area could help choose the most rational treatment tactics **(Figure 9).**

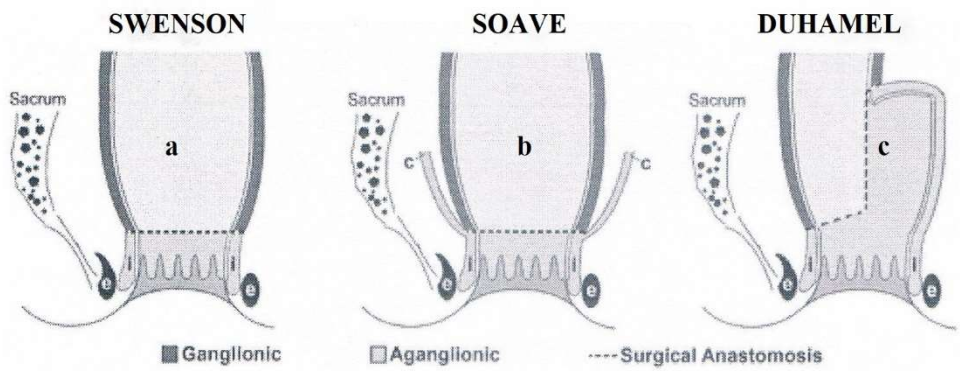

Figure 9. Schemes of operations in HD (from Smith et al [21]).

As can be seen from Figure 9, only Duhamel's operation, firstly, partially preserves the connection of the saved portion of the rectum with the levator plates. Second, in very short forms of HD, pressure-sensitive sensors can be located in the normally innervated rectum through which anorectal reflexes can be triggered. Studies of the pathophysiology of HD with different lengths of the aganglionic segments are required.

1877, Gowers discovered that the injection of air into the rectum causes a decrease in pressure in the anal canal [22]. The studies showed that the short-term pressure decrease in the upper part of the anal canal is due to the relaxation of the IAS (RAIR) [19,23]. In patients with congenital aganglionosis, this reflex is absent. In response to an increase of the rectal pressure a brief rise of the anal canal pressure arises [5].

Manometric detection of RAIR in children with chronic constipation is completely harmless and allows to exclude HD. In the case where the reflex is not detected, further examination is necessary to confirm or exclude HD. Nevertheless, over the past ten years, the percentage of manometric studies in Japan has decreased from 66.1% to 45.8% [24]. The same trend is observed in Europe. Only 31% of patients with HD had a manometric study [25]. The refusal of the manometric research is due to the fact that anesthesia is required to perform it. And since this study is done in a hospital, it is easier to perform a rectal biopsy and to make a final diagnosis.

From the middle of the 20th century, a manometric study was performing using a rectal balloon to determine the reaction of the anal canal to different volumes of the balloon. The depth and long-term relaxation of the IAS progressively increases with increasing balloon volume up to 71 cm^3 and thereafter does not change [26,27] (**Figure 10**).

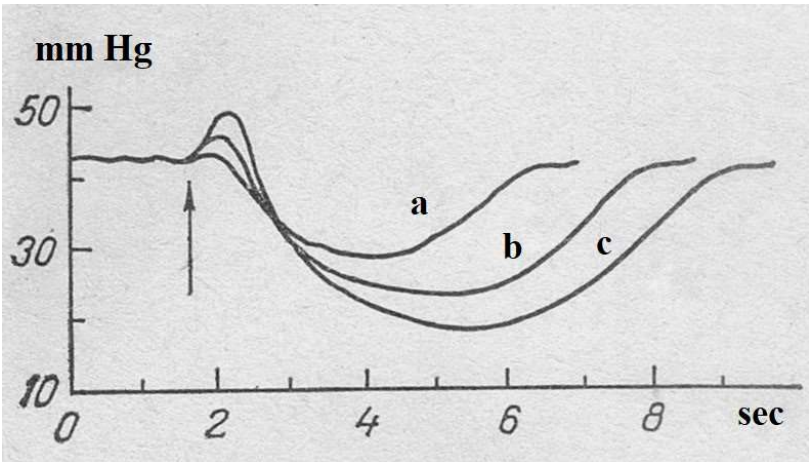

Figure 10. Graphs anal pressure (RAIR) following rapid injection of air into the rectum: (a) 30 cm³; (b) 50 cm³; (c) 70 cm³ [27].

Since for the diagnosis of HD, there is no need for quantitative characteristics, for its provocation, it is possible to inject air into the rectum, eliminating the need for administration of the rectal balloon under anesthesia [28]. Direct injection of air into the anal canal in newborns to provoke the reflex was performed by Kumar and co-authors. They just like us [27,28] did not find a difference in the volume of air needed to stimulate the RAIR compared with the introduction of air into the rectal balloon [29]. The use of highly sensitive equipment without the introduction of a rectal balloon allows this procedure to be performed without anesthesia on an outpatient basis.

Thus, in order to increase the chances of detecting RAIR with minimal exposure to ionizing radiation and/or with a manometric examination, a rapid introduction of the maximum volume of air into the rectum is necessary (from 20 cm³ for an infant to 70 cm³ for an older child). When air is slowly introduced, it spreads through the colon without causing noticeable relaxation of the BAC. The rapid introduction of air causes a sharp rise in rectal pressure, which increases the depth and duration of the RAIR. Air has an advantage over liquid because the viscosity of the liquid reduces the speed of its movement along the thin probe. To provoke RAIR, von Steyern et al used a cold, water-soluble contrast agent, which irritated the rectal wall, increased its tone, and thus increased rectal pressure. Another

reason to use maximum air volumes is that the amplitude of the rectoanal inhibitory reflex in patients with megarectum and constipation was decreased as compared to controls, sometimes mimicking the findings of Hirschsprung's disease, but increasing rectal distension always induced a relaxation of the internal anal sphincter [30,31]. The use of air as a contrast agent makes it possible to assess both anatomical and functional (RAIR) characteristics (**Figure 11.a**) [32]. However, positive contrast media is required to define the transition zone (**Figure 11b).**

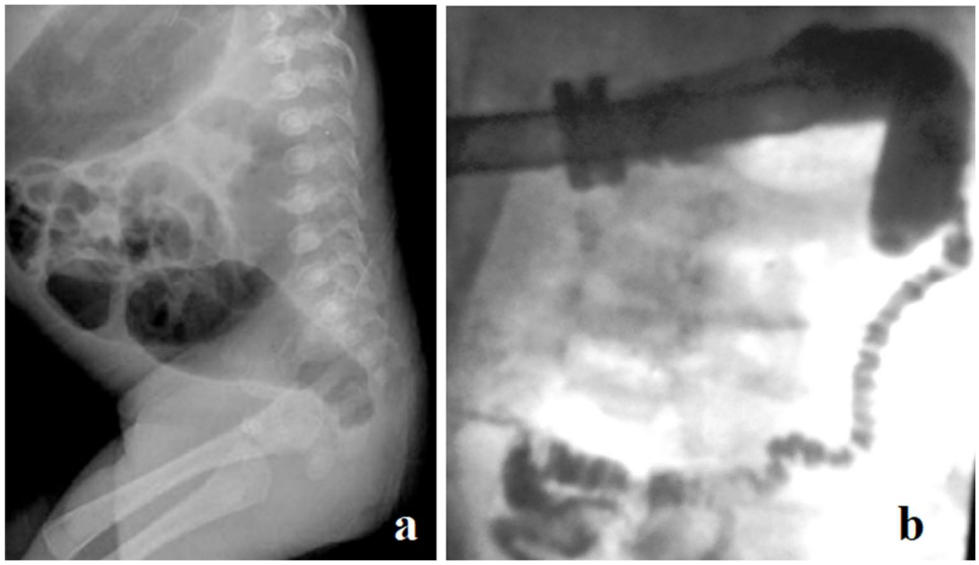

Figure 11. HD with short (a) and long (b) aganglionic segments.

Conclusion With a combination of anatomical and functional symptoms, the characteristic of HD, the accuracy of the diagnosis approaches 100%. It is sufficient to determine a combination of two reliable symptoms that exclude HD to stop further research. The totality of all radiologic symptoms of HD increases the reliability of diagnosis, as they reflect the pathological physiology of this disease.

References

1. Langer JC[1]. (2013) Hirschsprung disease. Curr Opin Pediatr. Jun;25(3):368-74. doi: 10.1097/MOP.0b013e328360c2a0. PubMed.
2. Butler Tjaden NE[1], Trainor PA. (2013) The developmental etiology and pathogenesis of Hirschsprung disease. Transl Res. Jul;162(1):1-15. doi: 10.1016/j.trsl.2013.03.001. PubMed.

3. Pratap A[1], Gupta DK, Tiwari A, et al. (2007) Application of a plain abdominal radiograph transition zone (PARTZ) in Hirschsprung's disease. BMC Pediatr. Jan 27;7:5. DOI:10.1186/1471-2431-7-5. PubMed.
4. Butler Tjaden NE, Trainor PA. The developmental etiology and pathogenesis of Hirschsprung disease. Transl Res. 2013 Jul;162(1):1-15. doi: 10.1016/j.trsl.2013.03.001.
5. Ambartsumyan L, Smith C, Kapur RP. Diagnosis of Hirschsprung Disease. Pediatr Dev Pathol. Jan-Feb 2020;23(1):8-22. doi: 10.1177/1093526619892351.
6. Kessmann J. Hirschsprung's disease: diagnosis and management. Am Fam Physician. 2006 Oct 15;74(8):1319-22.
7. Jarvi K, Koivusalo A, Rintala RJ, Pakarinen MP. Anorectal manometry with reference to operative rectal biopsy for the diagnosis/exclusion of Hirschprung's disease in children under 1 year of age. Int J Colorectal Dis. 2009 Apr;24(4):451-4. doi: 10.1007/s00384-008-0612-z.
8. de Lorijn, F, Kremer, LC, Reitsma, JB, Benninga, MA. Diagnostic tests in Hirschsprung disease: a systematic review. J Pediatr Gastroenterol Nutr 2006; 42: 496–505. doi: 10.1097/01.mpg.0000214164.90939.92.
9. Nusslé D, Genton N, Bozic C. Functional radiological findings in Hirschsprung's disease and in other cases of dyschezia. Ann Radiol (Paris). Jan-Feb 1976;19(1):111-22.
10. Levin MD, Korshun Z, Mendelson G. Method of X-Ray study of an anorectal area. Eksp Klin Gastroenterol (Moscow) 2011; 12: 15-21.
11. Ornö A, Lövkvist H, Marsál K, et al. Sonographic visualization of the rectoanal inhibitory reflex in children suspected of having Hirschsprung disease: a pilot study. J Ultrasound Med. 2008 Aug;27(8):1165-9. doi: 10.7863/jum.2008.27.8.1165.
12. von Steyern KV, Wingren P, Wiklund M, et al. Visualisation of the rectoanal inhibitory reflex with a modified contrast enema in children with suspected Hirschsprung disease. Pediatr Radiol. 2013 Aug;43(8):950-7. doi: 10.1007/s00247-013-2622-4.
13. Levin MD. Reaction to Koppen et al., 'Assessing colonic anatomy normal values based on air contrast enemas in children younger than 6 years'. Pediatr Radiol. 2018 Oct;48(11):1674-1677. doi: 10.1007/s00247-018-4181-1.
14. Levin MD. The role of the external anal sphincter in the physiology of the pelvic floor. Pelviperineolohy. 2017; 36(4):108-112. (Open access).
15. Ouladsaiad M. How to manage a late diagnosed Hirschsprung's disease. Afr J Paediatr Surg. 2016 Apr-Jun;13(2):82-7. doi: 10.4103/0189-6725.182562.
16. de Lorijn F , Kremer LCM, Reitsma LB, Benninga MA. Diagnostic tests in Hirschsprung disease: a systematic review. J Pediatr Gastroenterol Nutr. 2006 May;42(5):496-505. doi: 10.1097/01.mpg.0000214164.90939.92.

17. Wong CW[1], Lau CT, Chung PH, et al. (2015) The value of the 24h delayed abdominal radiograph of barium enema in the diagnosis of Hirschsprung's disease. Pediatr Surg Int. Jan;31(1):11-5. doi: 10.1007/s00383-014-3632-5. PubMed.
18. Wang J, Mou Y, Zhang Q, et al. Expression and significance of neuroligins in myenteric cells of Cajal in Hirschsprung's disease. PLoS One. 2013 Jun 28;8(6):e67205. doi: 10.1371/journal.pone.0067205. Print 2013.
19. Porter NH. A Physiological Study of the Pelvic Floor in Rectal Prolapse Arris and Gale Lecture delivered at the Royal College of Surgeons of England on 1st November 1960. Ann R Coll Surg Engl. 1962 Dec; 31(6): 379–404.
20. Shafik A, Mostafa RM, Shafik I, et al. Functional activity of the rectum: A conduit organ or a storage organ or both? World J Gastroenterol 2006 Jul 28;12(28):4549-52. doi: 10.3748/wjg.v12.i28.4549.
21. Smith C, Ambartsumyan L, Kapur RP. Pediatr Dev Pathol. Jan-Feb 2020;23(1):23-39. doi: 10.1177/1093526619889436.
22. Gowers WR. (1877) The autonomic action of the sphincter ani. Proceedings of the Royal Society (London).;26:77-81. PubMed.
23. Meunier P, Mollard P. (1977) Control of the internal anal sphincter (manometric study with human subjects). Pflugers Archiv.; 370: 233-9. PubMed.
24. Taguchi T[1,2], Obata S[3,4], Ieiri S[3,5]. (2017) Current status of Hirschsprung's disease: based on a nationwide survey of Japan. Pediatr Surg Int. Apr;33(4):497-504. doi: 10.1007/s00383-016-4054-3. PubMed.
25. Zani A[1], Eaton S[2], Morini F[3], et al. (2017)European Paediatric Surgeons' Association Survey on the Management of Hirschsprung Disease. Eur J Pediatr Surg. Feb;27(1):96-101. doi: 10.1055/s-0036-1593991. PubMed.
26. Cheeney G, Nguyen M, Valestin J, Rao SSC. Topographic and manometric characterization of the recto-anal inhibitory reflex (RAIR). Neurogastroenterol Motil. 2012 Mar;24(3):e147-54. doi: 10.1111/j.1365-2982.2011.01857.x.
27. Levin MD. Function of the anorectal zone in norm and in Hirschsprung disease. Zdravookhraneniye Belorussii. 1986 (5):30-33.
28. Levin MD. (2013) The pathological physiology of the anorectal defects, from the new concept to the new treatment. Eksp Klin Gastroenterol. (11):38-48. PubMed.
29. Kumar S[1], Ramadan S, Gupta V, et al. (2009) Manometric tests of anorectal function in 90 healthy children: a clinical study from Kuwait. J Pediatr Surg. Sep;44(9):1786-90. doi: 10.1016/j.jpedsurg.2009.01.008.
30. Verduron A, Devroede G, Bouchoucha M, et al. Megarectum. Dig Dis Sci. 1988 Sep;33(9):1164-74. doi: 10.1007/BF01535795.
31. Xu X, Pasricha PJ, Sallam HS, et al. Clinical significance of quantitative assessment of rectoanal inhibitory reflex (RAIR) in patients with

constipation. J Clin Gastroenterol. 2008 Jul;42(6):692-8. doi: 10.1097/MCG.0b013e31814927ba.
32. Sumida W, Uchida H, Ono Y, et al. Air test as a simple method of screening for Hirschsprung's disease. Clin Radiol. 2018 Dec;73(12):1041-1045. doi: 10.1016/j.crad.2018.08.008.